



Cranio-maxillofacial  
**Implant Directions®**

Vol.14 N° 4

December 2020

English Edition



POSSIBILITIES OF DENTAL IMPLANTS INSTALLATION "BYPASSING"  
INFERIOR ALVEOLAR NERVE: RESULTS OF CBCT ANALYSIS AND OWN EXPERIENCE  
VARES YA.E., GUDZAN YA.S., STUDENT V.O. , VARES YA.YA.

ISSN 1864-1199 / e-ISSN 1864-1237

OFFPRINT

## Editorial board

### Managing editor

Dr. Łukasz Pałka  
regmed.klinika@gmail.com

Dr. Vivek Gaur  
drvivekgaur@yahoo.co.in

### Coordinating editor

Joanna Dołbaczuk  
j.dolbaczuk@gmail.com

### Editorial board (in alphabetic order)

Dr. Muhammad Alobayat, Palestine  
Dr. Pablo Diaz, Equador  
Dr. Anita Doshi, India  
Dr. Marcos Daniel Gonzales, Colombia  
Dr. Georg Huber, Germany  
Prof. Dr. Vitomir S. Konstantinovic, Serbia  
Dr. Alexander Lazarov, Bulgaria  
Dr. Igor Lell, Germany  
Dr. Valeri Lysenko, Ukraine  
Dr. Werner Mander, Spain  
Dr. Juri Mitrushenkov, Russia  
Dr. Mahendra Perumal, India  
Dr. Andrii Shmojlov, Russia  
Dr. Pablo Diaz, Equador  
Prof. Dr. Jan Vares, Ukraine

### Evidence reports and Critical Appraisals

IF Research & Evidence Dept.

### Annual Subscription

Euro 2.800

### Copyright

Copyright ©2006 - 2020 by  
International Implant Foundation  
DE- 80802 Munich / Germany  
www.implantfoundation.org

### Contact

publishing@implantfoundation.org

### CMF.Impl.dir.

ISSN 1864-1199  
e-ISSN 1864-1237

## Disclaimer

### Hazards

Great care has been taken to maintain the accuracy of the information contained in this publication. However, the publisher and/or the distributor and/or the editors and/or the authors cannot be held responsible for errors or any consequences arising from the use of the information contained in this publication. The statements or opinions contained in editorials and articles in this publication are solely those of the authors thereof and not of the publisher, and/or the distributor, and/or the IIF.

The products, procedures and therapies described in this work are hazardous and are therefore only to be applied by certified and trained medical professionals in environment specially designed for such procedures. No suggested test or procedure should be carried out unless, in the user's professional judgment, its risk is justified. Whoever applies products, procedures and therapies shown or described in this publication will do this at their own risk. Because of rapid advances in the medical science, IF recommends that independent verification of diagnosis, therapies, drugs, dosages and operation methods should be made before any action is taken.

Although all advertising material which may be inserted into the work is expected to conform to ethical (medical) standards, inclusion in this publication does not constitute a guarantee or endorsement by the publisher regarding quality or value of such product or of the claims made of it by its manufacturer.

### Legal restrictions

This work was produced by IF Publishing, Munich, Germany. All rights reserved by IF Publishing. This publication including all parts thereof, is legally protected by copyright. Any use, exploitation or commercialization outside the narrow limits set forth by copyright legislation and the restrictions on use laid out below, without the publisher's consent, is illegal and liable to prosecution. This applies in particular to photostat reproduction, copying, scanning or duplication of any kind, translation, preparation of microfilms, electronic data processing, and storage such as making this publication available on Intranet or Internet.

Some of the products, names, instruments, treatments, logos, designs, etc. referred to in this publication are also protected by patents and trademarks or by other intellectual property protection laws (eg. «IF», «IIF» and the IF-Logo) are registered trademarks even though specific reference to this fact is not always made in the text.

Therefore, the appearance of a name, instrument, etc. without designation as proprietary is not to be construed as a representation by publisher that it is in the public domain.

Institutions' subscriptions allow to reproduce tables of content or prepare lists of Articles including abstracts for internal circulation within the institutions concerned. Permission of the publisher is required for all other derivative works, including compilations and translations. Permission of the publisher is required to store or use electronically any material contained in this journal, including any article or part of an article. For inquiries contact the publisher at the address indicated.



## Possibilities of Dental Implants Installation “bypassing” Inferior Alveolar Nerve: Results of CBCT analysis and own experience

### Authors

Ya.E. Vares<sup>1</sup>

Ya.S. Gudzan<sup>2</sup>

V.O. Student<sup>3</sup>

Ya.Ya. Vares<sup>2</sup>

### Key Words

cone-beam computed tomography; distal mandibular aspects; implantation; inferior alveolar nerve.

### How to cite this article

Ya.E. Vares, Ya.S. Gudzan, V.O. Student, Ya.Ya. Vares

Possibilities of Dental Implants Installation “bypassing” Inferior Alveolar Nerve: Results of CBCT analysis and own experience

CMF Impl Dir 2020; 14: 165 - 174

---

**1** Yan Vares, MD, PhD, DDS  
Professor & Head of Chair of Surgical Dentistry & Maxillofacial Surgery  
Lviv National Medical University  
named after Danylo Halytsky, Ukraine  
AO CMF European Faculty, ICOI, IIF  
Visiting professor of Jaipur Dental College (India)  
**2** Danylo Halytsky Lviv National Medical University, Department of Surgical Dentistry and Maxillofacial Surgery  
**3** Center for Medical 3D Diagnostics, Lviv

## Abstract

The problem of installation of dental implants in atrophied distal mandibular aspects is extremely relevant. From the point of view of classical two-stage implantation, the height deficiency of the alveolar process, due to the topographic proximity of the inferior alveolar nerve, requires the use of so called short or ultra-short implants or vertical augmentation of bone tissue using autologous, allogeneic, xenogeneic materials. Moreover, the installation of classical cylindrical or bullet-shaped implants is possible only in the presence of sufficient width of the alveolar process laterally or medially to the mandibular canal. The invention of single-piece cone-shaped implants of different lengths and diameters has allowed to realize the idea of their installation “bypassing” the inferior alveolar nerve, minimizing or avoiding the need for additional surgery to increase bone volume. This work demonstrates our own approach to the rehabilitation of patients with dentition defects in the distal mandible by precise analysis of computed tomography scans of patients and the installation of implants “bypassing” the inferior alveolar nerve.

## Introduction

It is known that in cases of atrophy of the distal mandibular aspects, the possibility of dental implantation is often limited by the lack of required height of the alveolar ridge due to the proximity of the mandibular canal, which requires short or ultra-short implants or vertical augmentation

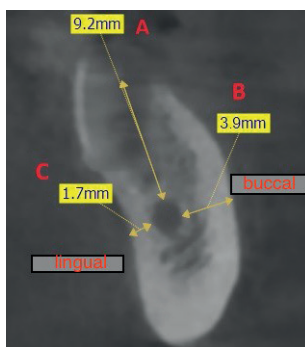
[12]. In the first case, the question of the unfavorable relation between the height of the implant and the prosthetic structure, as well as the proximity of the latter to the mobile vestibular mucosa remains debatable, which complicates, in particular, the necessary hygienic measures in peri-implant areas. In the second case, despite the presence of well-documented results of various vertical augmentation techniques using autologous, allogeneic, xenogeneic materials, etc., their disadvantage will always be an increase in the number of surgeries with additional trauma and higher risk of surgical complications, as well as increasing the overall rehabilitation time. [8]. The invention of single-piece cone-shaped implants of different lengths and diameters has allowed to realize the idea of their installation “bypassing” the inferior alveolar nerve, minimizing or avoiding the need for additional surgery to increase bone volume.

**The aim of the study** is to find out the features of the morphology of the edentulous distal parts of the mandible on the basis of analysis of computed tomography of patients, to propose a technique for dental implants installation “bypassing” the inferior alveolar nerve.

## Materials and methods

In accordance with the Agreement on Scientific Cooperation between the Department of Surgical Dentistry of Danylo Halytsky National Medical University (LNMU) and the Center for Medi-

cal 3D Diagnostics and after approval of the research protocol by the Commission of Bioethics of LNMU, 30 computed tomography scans of the mandible of patients (12 women, 18 men aged 36–68 years) who applied for the study during 2018–2020 were selected. Criteria for inclusion in the study were free-end defects of the mandible (at least - the absence of three lower molars) with varying degrees of atrophy of the alveolar process in this area. Exclusion criteria were the presence of mandibular molars, acquired defects of the alveolar process due to previous surgery (removal of jaw cysts, tumors, etc.), which could distort the clarity of visualization of certain anatomical structures and the necessary measurements. If the patient has bilateral free-end defects, measurements were performed on only one of them, which was selected by randomization. Criteria such as the distance from the apex of the alveolar ridge to the upper edge of the mandibular canal (A) and the distance from the lateral walls of the mandibular canal to the vestibular (B) and lingual (C) cortical plates of the mandible were taken into account (Fig. 1).



**Fig. 1.** Schematic representation of the method of measuring the distance from the mandibular canal to the lingual (C), vestibular (B) cortical plates and the top of the alveolar ridge (A).

Patients were examined on a Vatech Pax-i3D Green cone-beam computed tomography scanner (South Korea). The scan was performed in 9x12 cm mode, with a voxel size of 0.2 mm, which allowed to obtain maximum visualization of small anatomical elements of the jaws. Computed tomography results were processed using the Ez3D2009 and Xelis Dental (South Korea) imaging software.

In the clinic of the Department of Surgical Dentistry and Maxillofacial Surgery of LNMU 16 patients (men - 7, women - 9) aged 45-66 years with uni-, bilateral free-end defects or complete absence of mandibular teeth were examined and treated. All patients gave written consent to participate in the study. After finding out the location of the mandibular canal based on the analysis of CBCTs in coronal projection, single-piece dental implants (Ihde Dental AG, Switzerland) were installed in the distal parts of the mandible, “bypassing” the inferior alveolar nerve with immediate loading of the prosthetic structure within 3-4 days after implantation. Follow-up CT scans were performed 1-4 days after implantation. The effects of hypoesthesia or anesthesia in the area of distribution of the alveolar inferior or mental nerves, which could indicate their mechanical damage or compression, were also taken into account.

Statistical evaluation of the obtained results was performed using the IBM SPSS v.25.0 statistics software (IBM Corp., Armonk, NY, USA).

## Research results

Based on the study of 30 computed tomography scans of the mandible of patients with unilateral and bilateral free-end defects of the mandible (women - 12, men - 18, aged 36-68 years), who applied for research during 2018-2020 to the Center for Medical 3D diagnostics (Lviv) we found that the average distance from the mandibular canal to the vestibular cortical plate is  $5.12 \pm 1.04$  mm, to the lingual cortical plate -  $2.95 \pm 0.89$  mm, to the top of the alveolar process -  $6, 18 \pm 1.9$  mm ( $p < 0.001$ ).

Our results, as well as information from similar studies conducted earlier by other specialists [1,6,9,13], allowed us to implement the idea of installation of single-piece cone-shaped implants "bypassing" the inferior alveolar nerve.

In the clinic of the Department of Surgical Dentistry and Maxillofacial Surgery of LNMU, 16 patients (men - 7, women - 9) aged 45-66 years with uni-, bilateral free-end defects or complete absence of mandibular teeth were treated using 42 single-stage cone-shaped dental implants (KOS®, KOS® X, KOS® Micro, Ihde Dental AG, Switzerland) "bypassing" the inferior alveolar nerve on the lingual side. It is important that in some cases, depending on the clinical and radiological situation, single-stage implants with a bendable neck were used, which allowed to place the abutment head in the most correct prosthetic position by manual bending of the implant neck even under conditions of angular insertion

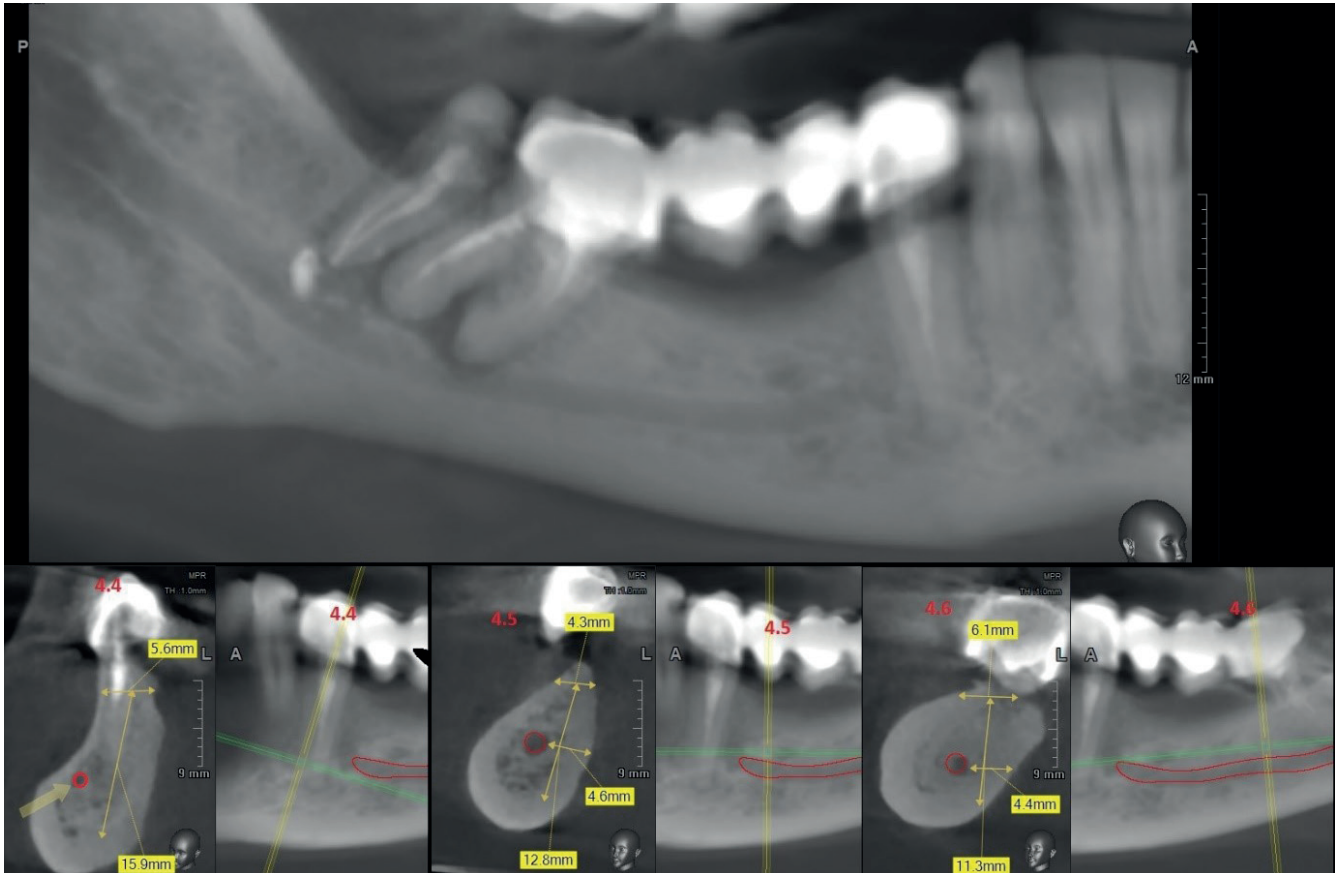
of the implant body into the bone tissue. For 4-5 days, all implants were loaded with a temporary metal-acrylic prosthetic structure. In a follow-up CT scan, the position of the implants in relation to the location of the mandibular canal, lingual, or vestibular cortical plates was assessed. In cases of patients complaining about postoperative hypoesthesia or anesthesia in the area of distribution of the inferior alveolar or mental nerves, which could indicate their mechanical damage or compression, glucocorticoids (Dexamethasone - 8-12 mg / d.) and vitamins (Neurorubine-Forte Lactab - 1 t. / 2t a day) were administered.

According to the results of follow-up computed tomography scans of patients performed 1-4 days after implantation, no complications in the form of direct mechanical damage to the walls of the mandibular canal or cortical plates with surgical tools (drills) or directly by the implant body were found. In some cases, CBCT scans showed contact of the lateral surface of the implant body to the mandibular canal wall, which caused compression of the inferior alveolar nerve and was clinically manifested by temporary hypoesthesia or anesthesia in the innervation zone of the respective nerves and required the use of aforementioned medication. These complaints disappeared within a month after implantation. None of the patients complained of decreased or lost sensitivity in the alveolar process and soft tissues of the mandible.

As an example, we introduce the following clinical case.

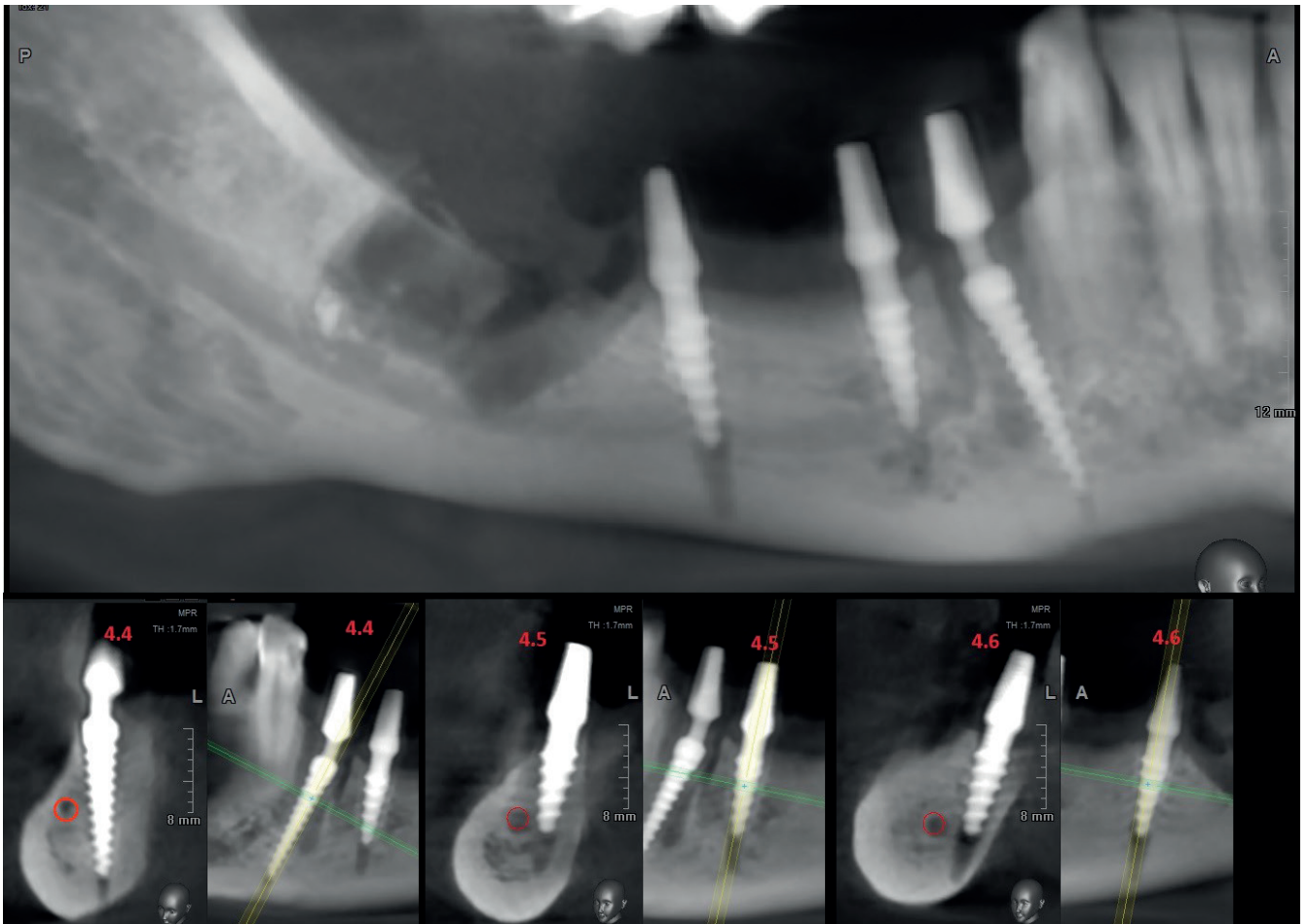
Patient S., born in 1972, came to the clinic of the Department of Surgical Dentistry of LNMU with complaints of tooth pain located in the lower jaw on the left, mobility of the bridgework in the area of teeth 44-47. During the radiological examination, the presence of periapical inflammation in the area of the root apex of 44, 47, 48 teeth was revealed (Fig. 2). After a thorough analysis of CBCT scans with schematic visualization of anatomical formations of the distal lower jaw on the left, the conduction of necessary measurements and explanation of alternative therapeutic options, the patient was offered a treatment plan that included removal of teeth 44, 47, 48, bone curettage and installation of 3 single-piece implants in the area of teeth 44, 45, 46 "bypassing" the inferior alveolar nerve. After obtaining written consent for treatment under local anesthesia with premedication, teeth 44, 47, 48 were removed, thorough mechanical and medical curettage of the inflammation area was performed, and 3 single-piece cone-shaped implants KOS<sup>®</sup>, KOS<sup>®</sup> Micro (Ihde Dental AG, Switzerland) were installed in the area of teeth 44, 45, 46 (size 3.7/12 mm; 4.1/8 mm; 4.1/8 mm, respectively) "bypassing" the inferior alveolar nerve on the lingual side. At the follow-up CBCT 2 days after implantation, the presence of all 3 implants from the lingual side of the mandible without involvement or damage to the walls of the mandibular canal or lingual cortical plate (Fig. 3) was ascer-

ained. Moreover, the implant in the area of tooth 44 was inserted with mesial angulation considering the location of the loop of the mental nerve, and the head of the abutment was subsequently paralleled to the others by manual bending of the flexible neck of the implant. 3 days after the operation, the temporary metal-acrylic bridge structure was fixed on the implants under full occlusal loading.



**Fig. 2.** Reformatted CBCT scan, panoramic view. Patient S., born in 1972, before implantation. Chronical periodontitis of teeth 44, 47, 48. Graphic visualization of the mandibular canal with measurements of the height of the mandible and the distance from the mandibular canal to the lingual cortical plate.





**Fig. 3.** Reformatted CBCT scan, panoramic view. Patient S., born in 1972, 2 days after implantation. Teeth 44, 47, 48 extracted. Graphic visualization of the mandibular canal. Installation of 3 single-piece implants on the lingual side of the mandible “by-passing” the inferior alveolar nerve.

## Discussion

Many publications have been devoted to determining the size and morphology of the distal mandible as a necessary diagnostic measure at the stage of dental implant planning, which indicates the urgency of the problem of potential damage to the inferior alveolar nerve during implant placement [3,10].

In the work of Japanese scientists [13], which included the study of 79 computed tomograms of patients of different sexes, it was noted that the distance from the mandibular canal to the top of the alveolar ridge was 15.3–17.4 mm, but the authors did not provide information about the patient age and their dental status, which would allow to speak about certain atrophic changes of the distal parts of the mandible. A similar study, performed by L.A. de Souza et al. [11] indicates that only in 18.3% of the 100 patients examined, the height of the alveolar process (to the mandibular canal) allows the installation of standard ( $\approx 10$  mm) implants, while the remaining cases require the use of short implants or bone augmentation. A more precise study of the morphology of the mandible in its distal aspects was conducted by S. Bayrak et al. [1] based on the analysis of 500 computed tomograph scans (1000 halves of the mandible) of patients aged 10–87 years. The authors found that the average distance from the mandibular canal to the vestibular cortical plate is  $5.02 \pm 1.32$  mm, and to the lingual cortical plate -  $1.4 \pm 0.85$  mm, and there are significant differences depending on gender and sides of

the study (right or left). According to Brazilian scientists [6], who studied the topography of the mandibular canal in 50 people aged 25–75 years of different sexes, the average distance from the canal to the vestibular cortical plate is  $6.1 \pm 1.5$  mm, to the lingual cortical plate -  $3.9 \pm 1.1$  mm, to the top of the alveolar process -  $16.9 \pm 2.8$  mm. Instead, in a study by M.G. Sghaireen et al. [9] indicates that the distance from the mandibular canal to the lingual cortical plate in edentulous patients is more than 6 mm regardless of age, sex or side of the jaw, which indicates the possibility of implants “bypassing” the mandibular canal on the lingual side.

According to C. de Oliveira-Santos et al. [8] an important factor that directly affects the distance from the canal to the lingual and vestibular cortical plates is the diameter of the canal itself, which can range from 2.1 to 4.0 mm.

Based on the study of CBCT 30 dried jaw models with complete or partial absence of teeth S.R. Daroz et al. [2] concluded that in 28.3% of cases it is possible to install standard implants with a diameter of 3.75 mm by lateral bypass of the mandibular canal, which makes this technique an alternative to more complex techniques, such as vertical augmentation.

Instead, according to other researchers, the procedure of implant placement bypassing the inferior alveolar nerve on the lingual side may be accompanied by perforation of the lingual cortical plate during dissection of the implant bed

and lead to serious complications in the form of massive bleeding followed by airway obstruction [4,5], which once again indicates the feasibility of careful planning of the procedure of implant placement in the atrophied distal parts of the mandible.

## Conclusions

Undoubtedly, this study is preliminary and requires the processing of much more clinical material and analysis of long-term (up to 5-10 years) observations. However, the results of our own experience, which are fully consistent with the reports of other researchers, suggest that the installation of dental implants in the distal mandible “bypassing” the inferior alveolar nerve creates a serious alternative to traditional methods of vertical augmentation, allows the fast rehabilitation of the dental-maxillary system due to the implementation of the protocol of immediate loading of implants. At the same time, the procedure of implant placement “bypassing” the inferior alveolar nerve on the lingual side requires in-depth knowledge of the anatomy of the maxillofacial area and careful planning with use of CBCT.

## References

1. Bayrak S, Demirturk-Kocasarac H, Yaprak E, Ustaoglu G, Noujeim M. Correlation between the visibility of submandibular fossa and mandibular canal cortication on panoramic radiographs and submandibular fossa depth on CBCT. *Med. Oral Patol. Oral Cir. Bucal.* 2018;V.23(1): 105–111.
2. Daroz SR, Cardoso ES, Manso MC, Vidigal GM. Evaluation of bone width lateral to the mandibular canal as an alternative approach for implant installation. *Implant. Dent.* 2013; V.22 (1): 97-101.
3. Juodzbalys G, Wang HL, Sabalys G, Sidlauskas A, Galindo-Moreno P. Inferior alveolar nerve injury associated with implant surgery. *Clin. Oral. Implants Res.* 2013; V.24(2); 183-190.
4. Isaacson TJ. Sublingual hematoma formation during immediate placement of mandibular endosseous implants. *J. Amer. Dent. Assoc.* 2004; V.135(2): 168-172.
5. Niamtu J. Near-fatal airway obstruction after routine implant placement. *Oral Surg. Oral Med. Oral Pathol. Oral Radiol. Endod.* 2001; V.92(6): 597-600.
6. de Oliveira Júnior MR, Santos Saud AL, Fonseca DR, De-Ary-Pires B, Pires-Neto MA, de Ary-Pires R. Morphometrical analysis of the human mandibular canal: a CT investigation. *Surg. Radiol. Anat.* 2011;V. 33(4): 345-352.
7. de Oliveira-Santos C, Couto Souza PH, de Azambuja Berti-Couto S, Stinkens L, Moyaert K, Fischer Rubira-Bullen IR, Jacobs R. Assessment of variations of the mandibular canal through cone beam computed tomography. *Clin. Oral Investig.* 2012; V.16(2): 387-393.
8. Scortecchi G. *Basal Implantology.* 2019. Cham: Springer Nature, 398 p.
9. Sghaireen MG, Srivastava KC, Shrivastava D, Ganji KK, Patil SR, Abuonq A. A CBCT Based three-dimensional assessment of mandibular posterior region for evaluating the possibility of bypassing the inferior alveolar nerve while placing dental implants. *Diagnostics.* 2020; V.10(6): 406.
10. Shavit I, Juodzybalis G. Inferior alveolar nerve injuries following implant placement – importance of early diagnosis and treatment: a systematic review. *J. Oral Maxillofac. Res.* 2014; V.5(4): e.2
11. de Souza LA, Souza Picorelli Assis NM, Ribeiro RA, Pires Carvalho AC, Lopes Devito K. Assessment of mandibular posterior regional landmarks using cone-beam computed tomography in dental implant surgery. *Ann. Anat.* 2016; V.205: 53-59.
12. Thoma DS, Cha JK., Jung UW. Treatment concepts for the posterior maxilla and mandible: short implants versus long implants in augmented bone. *J. Periodont. Implant Sci.* 2017; V.47(1): 2.
13. Watanabe H, Mohammad Abdul M, Kurabayashi T, Aoki H. Mandible size and morphology determined with CT on a premise of dental implant operation. *Surg. Radiol. Anat.,* 2010; V.32(4): 343-349.