



Cranio-maxillofacial

Implant Directions®

Vol. 10 N° 2

June 2015

English Edition



CASE REPORT:
REPLACING CONGENITAL MISSING INCISOR TOOTH IN AN HOUR

GARG A., BATRA R., KUMAR M., SINGH M.

ISSN 1864-1199 / e-ISSN 1864-1237

OFFPRINT



The Foundation of Knowledge

Editorial board

Managing editor

Dr. Vivek Gaur
drvivekgaur@yahoo.co.in

Dr. Narender Singh
omsaidental@yahoo.com

Coordinating editor

N. N.

Editorial board (in alphabetic order)

Dr. Yassen Dimitrov, Bulgaria
Za. Stephan Haas, Germany
Dr. Mayur Khairnar B.D.S., M.D.S., F.I.C.O.I
Prof. Dr. Vitomir S. Konstantinovic, Serbia
Dr. Valeri Lysenko, Ukraine
Katarina Markova, Prague
Jura Mitruschenkow, Moskow
Dr. Gerald Schillig, Germany
Dr. Katrin Tost, Greece

Evidence reports and Critical Appraisals

IF Research & Evidence Dept.

Single Issue Price

Euro 30

Annual Subscription

Euro 120

Copyright

Copyright ©2006 - 2015 by
International Implant Foundation
DE- 80802 Munich / Germany
www.implantfoundation.org

Contact

publishing@implantfoundation.org

CMF.Impl.dir.

ISSN 1864-1199
e-ISSN 1864-1237

Disclaimer

Hazards

Great care has been taken to maintain the accuracy of the information contained in this publication. However, the publisher and/or the distributor and/or the editors and/or the authors cannot be held responsible for errors or any consequences arising from the use of the information contained in this publication. The statements or opinions contained in editorials and articles in this publication are solely those of the authors thereof and not of the publisher, and/or the distributor, and/or the IIF.

The products, procedures and therapies described in this work are hazardous and are therefore only to be applied by certified and trained medical professionals in environment specially designed for such procedures. No suggested test or procedure should be carried out unless, in the user's professional judgment, its risk is justified. Whoever applies products, procedures and therapies shown or described in this publication will do this at their own risk. Because of rapid advances in the medical science, IF recommends that independent verification of diagnosis, therapies, drugs, dosages and operation methods should be made before any action is taken.

Although all advertising material which may be inserted into the work is expected to conform to ethical (medical) standards, inclusion in this publication does not constitute a guarantee or endorsement by the publisher regarding quality or value of such product or of the claims made of it by its manufacturer.

Legal restrictions

This work was produced by IF Publishing, Munich, Germany. All rights reserved by IF Publishing. This publication including all parts thereof, is legally protected by copyright. Any use, exploitation or commercialization outside the narrow limits set forth by copyright legislation and the restrictions on use laid out below, without the publisher's consent, is illegal and liable to prosecution. This applies in particular to photostat reproduction, copying, scanning or duplication of any kind, translation, preparation of microfilms, electronic data processing, and storage such as making this publication available on Intranet or Internet.

Some of the products, names, instruments, treatments, logos, designs, etc. referred to in this publication are also protected by patents and trademarks or by other intellectual property protection laws« (eg. «IF», «IIF» and the IF-Logo) are registered trademarks even though specific reference to this fact is not always made in the text.

Therefore, the appearance of a name, instrument, etc. without designation as proprietary is not to be construed as a representation by publisher that it is in the public domain.

Institutions' subscriptions allow to reproduce tables of content or prepare lists of Articles including abstracts for internal circulation within the institutions concerned. Permission of the publisher is required for all other derivative works, including compilations and translations. Permission of the publisher is required to store or use electronically any material contained in this journal, including any article or part of an article. For inquiries contact the publisher at the adress indicated.

Case Report

Replacing congenital missing incisor tooth in an hour.

Authors:

1. Dr. Ranmeet Batra, Professor, Himachal Institute Of Dental Sciences, Paonta Sahib
2. Dr. Abhinav Garg, Post Graduate Student, Himachal Institute Of Dental Sciences
3. Dr. Mrinal Kumar, Post Graduate Student, Himachal Institute Of Dental Sciences
4. Dr. Mahender Singh, Post Graduate Student, Himachal Institute Of Dental Sciences

Correspondence address:

Dr. Abhinav Garg
C/o Aggarwal clinic, Sunami gate,
Sangrur (punjab) India
Pin code-148001
Email: garg.abhinav04@gmail.com
Mob. No.: 09592971641

Abstract

Immediate or early loading of dental implants has been a hot topic in implantology. It shortens the treatment time and makes it possible to provide the patient with a functional and aesthetic reconstruction during the entire treatment period. In patients with low amount of bone, placement of basal implants and their cortical anchorage allows single step procedure of immediate loading a successful method. Patients suffering from congenital hypodontia have thin bony ridges due to absence of adequate growth stimuli are ideal for basal implantology.

Keywords: Hypodontia, Corticalization, Cortical Anchorage, KOS, Immediate Loading

1. Introduction

Implants have revolutionized the art and science of modern dentistry giving a new lease of life to the restorative aspects in day to day practice. It has transformed into a reliable and predictable treatment modality for fully and partially edentulous arches³. Immediate loading in conventional screw type implants has recently been evaluated with increasing results. A single-stage protocol has been standard in basal implantology for years. So the use of basal bone implants seems to be first choice in cases desiring fast, minimally invasive, durable and cost worthy implantological treatments^{1,2,3}.

2. Case

A 23-year-old female patient was referred to our department for implant treatment. Preceding orthodontic treatment modulated the arch while the upper left lateral incisor was missing congenitally (Fig. 1 & 2). In the absence of physiological forces, the inter-radicular distance between the root of central incisor and canine was markedly reduced. The vertical bone height was sufficient.

Patient wants the implant based crown as quick as possible. So we decided to use basal implant (KOS) in a single stage procedure and immediate loading of implant. As the ridge is very thin we decided to use KOS-B 3.0 x 15 mm implant by DR. IHDE DENTAL AG, Switzerland. (KOS – KING OF SINGLE PIECE IMPLANTS)

Under local anesthesia the drilling to prepare the implant bed is done (Fig. 3). Then the single piece KOS IMPLANT with fixed abutment was inserted very cautiously as the implant may fracture during tightening (Fig. 4 & 5). A good primary stability of the implant was achieved by the cortical bone and it also provides the sufficient load bearing capacity even in the narrow ridge. The patient left the department after an hour of treatment with prefabricated temporary plastic crown (Fig. 6 & 7).

To allow healing and proper shaping of the soft tissues (Fig. 9), the impression for the permanent crown was taken three months later. The treatment was finalized by cementing metal-to-ceramic crown. This procedure allowed achieving immediate function as well as immediate aesthetics. The patient is satisfied with the short intervention, the clinical result and the low costs.

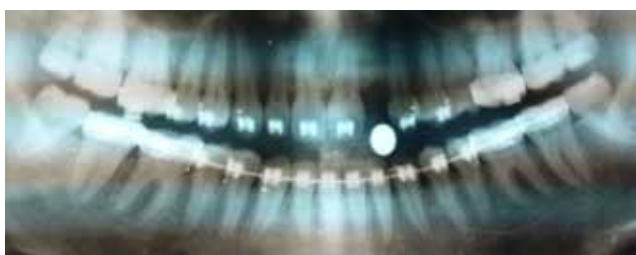


Fig. 1: Panoramic view shows horizontal deficits at the implant site.

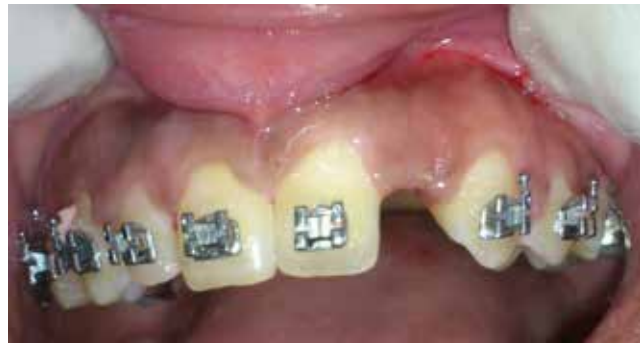

Fig. 2: Pre-operative image showing the edentulous space.

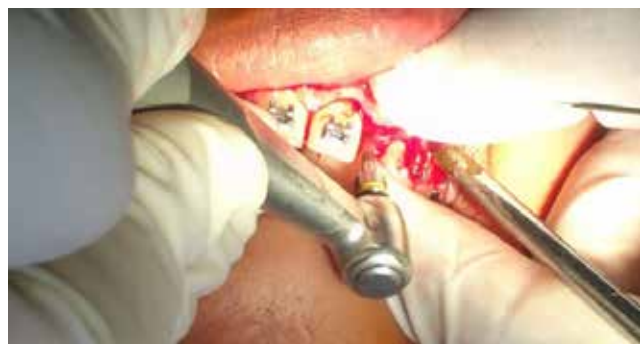

Fig. 3: Intraoperative image showing drilling

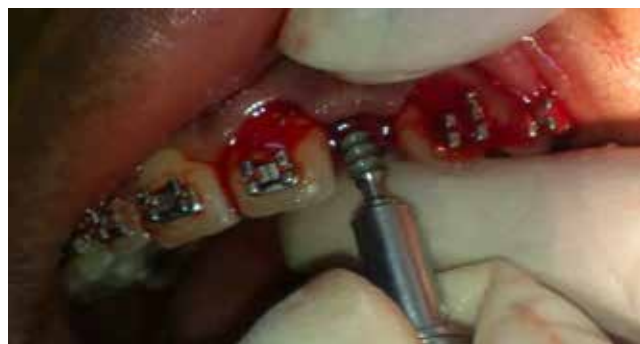

Fig. 4: Manual implant placement

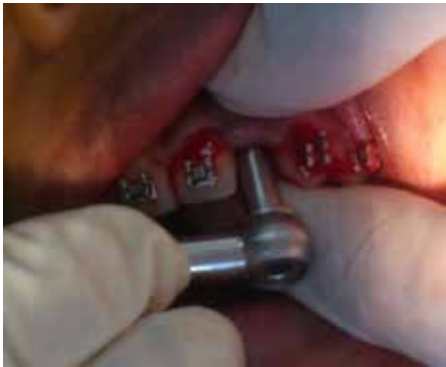

Fig. 5: Final insertion with torque ratchet.

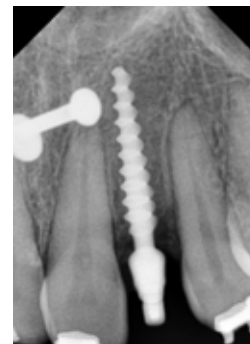
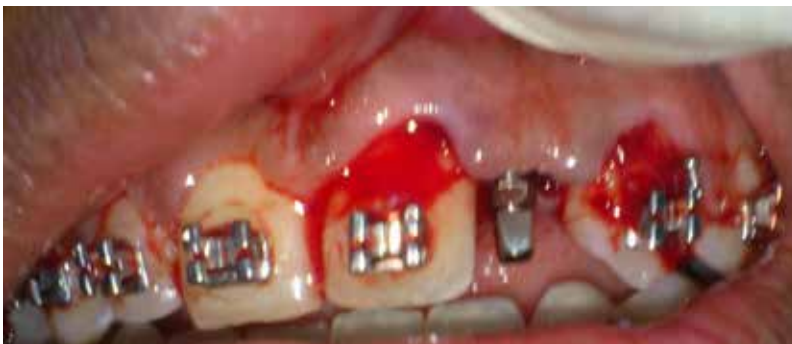
Fig. 6 & 7: Final position of implant

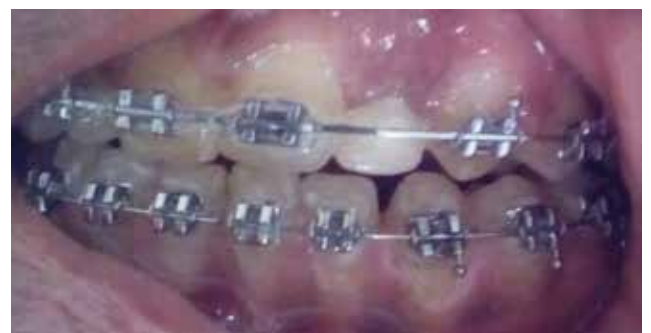
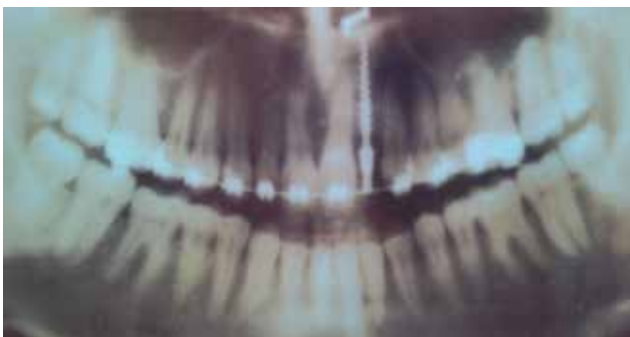
Fig. 8 & 9: Post operative follow up after 3 months showing good gingival healing.

3. Discussion

KOS implants are single piece implants which are designed in accordance with the compression screw principle⁶. The KOS implant systems in the recent years have been excellent because the system has several advantages. There are no screws that loosen over the years. The abutment is rigidly connected because it is integrated, and several abutment angulations are available, the abutment can be machined and some versions are even flexible^{1, 2, 4}.

In addition the implant can be placed transgingivally. This technique yielded optimal results even in the absence of any laborious and risky reflection or augmentation. Gingival penetration is only local, and the insertion site is sealed by the implant itself. There is no significant bleeding. This is particularly good for patients with blood clotting disorders who are not forced to discontinue their medication completely. Wound dressing is uncomplicated and there is no significant swelling^{2, 4}.

In the very narrow ridges KOS 3.0 mm and 3.2 mm implant can be inserted perfectly well by reflecting a mucoperiosteal flap. It gives long term success as close proximity of both cortical walls has already been established in this situation, so with very little or no cancellous bone been left, the screw threads will end up bilaterally in cortical bone structures².

Augmentations prior to the implantation can typically be avoided by the use of basal implants. With the physiological stimulus by basal implants on present bone, remodeling leads to new vital bone in areas of load transmission¹. Augmentation in areas which should be used for immediate load transmission are not possible,

because the augmentation material should first be integrated (which takes time). Intra-alveolar augmentations are sometimes done to stabilize callus next to the implant surface, but without any immediate function.

An implant of >10mm length appears to be the most successful if using root-form implants like KOS, requiring sufficient vertical bone to support the length of the implant⁵. The impression is taken immediately after the surgical procedure. Impression taking is very much like on natural teeth. Patient leaves the office with a temporary fixed restoration in place.

4. Conclusion

KOS implants are compression screw designed for single stage procedure. The installation of basal dental implants and their cortical anchorage leads to fast rehabilitation and high aesthetic results. Also patients with small depressed bone ridges in the absence of adequate growth stimulus benefit by the use of basal implants.

The surgery is done within one single session, temporary or sometimes permanent crowns or bridges can be implemented safely on the same day with long lasting success. There is lack of mobility, pain, pathologic problems and crestal bone loss. In short inserting KOS implants is relatively simple and safe with high success rate.

References

1. Kopp S (2007): Implantological treatment in a patient with hypodontia: CMF Impl Dir, 2(4):155-159.
2. Mander W (2009): Long-term study on immediate loading of one-piece KOS® implants with fixed complete dentures- Success of 678 one-piece KOS implants up to 9 years after transgingival placement without navigation. Dental: Spiegel, 1(2):2-7.
3. Abichandani SJ, Nadiger R (2013): Maxillary immediate implant loading: A comprehensive review: J of Dental Implants: 3(1):52-57.
4. Fabritius T (2007): One-piece, single stage and immediate loaded: DZW ORALE IMPLANTOLOGIE 3/07.
5. (2007) Literature analysis (poor bone) PART II: CMF Impl. Dir: 3(2): 91-98.
6. Ihde S (2008): The primary stability and survival rate of 2-stage, conical compression-screw implant: J of Maxillofacial & Oral Surgery: 7 (2): 273-277.

The International Implant Foundations announces that the successful Curriculum for Immediate Loading and the Clinical Master-degree in Immediate Loading and Basal Implantology will be available soon in the following location:

Step 1

Curriculum for Immediate Loading in Dental Implantology

Location:

Frankfurt - Airport

Duration: 4 sessions of 2 days.

Target group: Implantologists, Oral Surgeons, Maxillo-facial Surgeons, Dentists.

Dates: 27./28. 3. 2015 / 8./9. 5. 2015 / 12./13. 6. 2015 / 4./5. 9. 2015 (Budva)

Session 1:

Principles of Basal osseointegration; surgery and prosthetics, treatment planing, avoiding bone-augmentations and sinus-lifts even in difficult cases.

Session 2:

Bone physiology and choice of implant locations (4D-implantology)

Session 3:

Principles of the work with compression screws: surgery and prosthetics

Session 4:

Maintenance; Treatment of complex cases.

Step 2

Practical application

Case Presentation and / or Publications (for Credit Points)

Case Support

Locations:

Individual tuition in the offices of the participants and the teacher

Supervision: through the local coordinator

Step 3

Master of Immediate Loading

Master-Exam (written)

Location: Budva/Montenegro / 5./6. 9. 2015

Supervision: Through the regional coordinator

Requirements: IF-Curriculum (Step 1), additional Credit Points (Step 2)