

Cranio-maxillofacial

Implant Directions®

Vol. 12 N° 1

January 2017

English Edition



CASE REPORT:
ORAL REHABILITATION WITH FIXED PROTESES ON IMPLANTS IN VERY ATROPHIC
MAXILARS USING BASAL IMPLANTS AND MONOPHASIC IMPLANTS

PASTOR M., GARCÍA M.

ISSN 1864-1199 / e-ISSN 1864-1237

OFFPRINT

Editorial board

Managing editor

Dr. Łukasz Pałka
regmed.klinika@gmail.com

Dr. Vivek Gaur
drvivekgaur@yahoo.co.in

Coordinating editor

N. N.

Editorial board (in alphabetic order)

Dr. Yassen Dimitrov, Bulgaria
Za. Stephan Haas, Germany
Prof. Dr. Vitomir S. Konstantinovic, Serbia
Dr. Valeri Lysenko, Ukraine
Katarina Markova, Prague
Jura Mitruschenkow, Moscow
Dr. Gerald Schillig, Germany
Dr. Narender Singh, India
Dr. Katrin Tost, Greece

Evidence reports and Critical Appraisals

IF Research & Evidence Dept.

Single Issue Price

Euro 30

Annual Subscription

Euro 120

Copyright

Copyright ©2006 - 2015 by
International Implant Foundation
DE- 80802 Munich / Germany
www.implantfoundation.org

Contact

publishing@implantfoundation.org

CMF.Impl.dir.

ISSN 1864-1199

e-ISSN 1864-1237

Disclaimer

Hazards

Great care has been taken to maintain the accuracy of the information contained in this publication. However, the publisher and/or the distributor and/or the editors and/or the authors cannot be held responsible for errors or any consequences arising from the use of the information contained in this publication. The statements or opinions contained in editorials and articles in this publication are solely those of the authors thereof and not of the publisher, and/or the distributor, and/or the IIF.

The products, procedures and therapies described in this work are hazardous and are therefore only to be applied by certified and trained medical professionals in environment specially designed for such procedures. No suggested test or procedure should be carried out unless, in the user's professional judgment, its risk is justified. Whoever applies products, procedures and therapies shown or described in this publication will do this at their own risk. Because of rapid advances in the medical science, IF recommends that independent verification of diagnosis, therapies, drugs, dosages and operation methods should be made before any action is taken.

Although all advertising material which may be inserted into the work is expected to conform to ethical (medical) standards, inclusion in this publication does not constitute a guarantee or endorsement by the publisher regarding quality or value of such product or of the claims made of it by its manufacturer.

Legal restrictions

This work was produced by IF Publishing, Munich, Germany. All rights reserved by IF Publishing. This publication including all parts thereof, is legally protected by copyright. Any use, exploitation or commercialization outside the narrow limits set forth by copyright legislation and the restrictions on use laid out below, without the publisher's consent, is illegal and liable to prosecution. This applies in particular to photostat reproduction, copying, scanning or duplication of any kind, translation, preparation of microfilms, electronic data processing, and storage such as making this publication available on Intranet or Internet.

Some of the products, names, instruments, treatments, logos, designs, etc. referred to in this publication are also protected by patents and trademarks or by other intellectual property protection laws (eg. «IF», «IIF» and the IF-Logo) are registered trademarks even though specific reference to this fact is not always made in the text.

Therefore, the appearance of a name, instrument, etc. without designation as proprietary is not to be construed as a representation by publisher that it is in the public domain.

Institutions' subscriptions allow to reproduce tables of content or prepare lists of Articles including abstracts for internal circulation within the institutions concerned. Permission of the publisher is required for all other derivative works, including compilations and translations. Permission of the publisher is required to store or use electronically any material contained in this journal, including any article or part of an article. For inquiries contact the publisher at the address indicated.



ORAL REHABILITATION WITH FIXED PROTESIS ON IMPLANTS IN VERY ATROPHIC MAXILARS WITH BASAL IMPLANTS AND MONOPHASIC IMPLANTS

A Clinical Case solved with the Strategic Implant®

Authors

Dr. Miguel Alvarado Pastor

Dr. Manuel Espadas García

Dr. Miguel Alvarado Pastor

Avda. del Puerto Nº58- 34

46023 Valencia (Spain)

Tel.: (0034) 637370086

Mail: malvarado1169@hotmail.com

Dr. Manuel Espadas García &

Paseo Cordellas Nº9.1-2

08290 Cerdanyola del Vallés

Barcelona (Spain)

Tel.: (0034) 666569658

Mail: mespadasg@hotmail.com

Abstract

This article shows how to solve the case of a patient with a very advanced alveolar atrophy in both jaws, applying the rules of “Strategic Implantology” developed by Dr. Stefan Ihde and associated colleagues from the International Implant Foundation (IF), Munich/Germany. Because this system/procedure was the only promising approach, the patient decided to have “Strategic Implant®” placed in the upper jaw (BCS® brand model of Ø 3.5 and lengths of 20 mm, 17mm, 14mm and 10 mm, as well as ZSI® Zygomatic screw implants Ø 4.6 in the length of 50 mm. In the lower jaw, the clinical situation allowed to place single phase/piece

implants KOS® and KOS B® of Ø 3,0 - 3,2 - 3,7 and 4,1 of lengths of 12, 15, 10 and 6 mm.

All implants are made of Ti6Al4V Titanium alloy (Manufacturer: Dr Ihde Dental AG, 8737 Gommiswald, Switzerland). The use of these types of implants allows the rehabilitation of patients who present very atrophic jaws, and in immediate loading.

Following the rules applied “Strategic Implantology” the patient can (and must) be rehabilitated in an immediate load protocol, without having to undergo sinus lifts, bone grafts or lateralizations of the dental nerve. In addition the patient may use the new teeth immediately, thus re-establishing normal and adequate masticatory function, acceptable phonetics and good aesthetics on the same day with provisionals made from resin. Later we place the definitive zirconium prosthesis within 4 days. Today there is no need to wait for “biologic osseointegration” for 6-9 months or more, as in the traditional approach which also we had been performed earlier.

For cases of extreme atrophy, we even prefer to splint the implants with a metallic bar on the same day and to restore for a number of months with a removable denture, to allow gradual loading and periods of non-loading every day (by taking the denture out).

The high speed of therapy and the predictability of the treatment is greatly appreciated both by the patient and the treatment provider.

Keywords

- Strategic Implant®¹
- Basal Implantology
- BCS® Implants²
- ZSI® Implants
- KOS® Implants
- Immediate load Implants
- Avoiding Bone Grafts
- Avoiding Maxillary Sinus lift
- Bone Atrophy

1 Strategic Implant® is a registered trade-mark

2 KOS® & BCS® are registered trade-marks

Introduction

The traditional rehabilitation of patients with highly atrophic jaw bones involves treatments with a high degree of difficulty, because augmentations become part of the treatment plan. Such plans are usually set up for the old type of „biphasic“ implants which are still used frequently. A large number of patients is however excluded from dental implant treatment. They are being told that implants cannot be implanted because of lack of bone, or that they must undergo long and painful additional interventions, such as block bone grafts, sinus elevations or lateralization of the nerve, become treatable in one step with the treatment concept explained here. Typically patients refuse such treatments.

On the other hand patients nowadays demand more and more immediately effective solutions, as well as painless treatment and treatments which do not cause collateral damages. Also the cost-effectiveness of a treatment is an increasing concern of patients.

In this article, we demonstrate only some of the uncountable advantages of following the philosophy of work with the Strategic Implant®. This system/technology really and finally breaks the rules and dogmata that were established powerful in the (from our today's perspective) historical field of oral implantology. The technolo-

gy improves our treatment options, it is very bone based and yet innovative. The concept of the Strategic Implant® is a **true game changer** in the world of oral implantology, it's the easy to pass-through door to a new life both for patients and for treatment providers. In summary, these are the concepts of Strategic Implant®:

Discipline and protocol in the preparation of the prosthesis

The prosthesis must follow very easy but strict parameters, such as; The splinting of the implants in the framework of a rigid structure, the shape of the rounded parts without sharp edges and of course, a very stable occlusion, leaving the posterior areas (behind the 1st molar) free from teeth and contacts. And all can be done in a time record.

Precise surgery is the basis of the treatment

Any surgery, whatever it may be, should always be well planned. But with Strategic Implant®, especially when we work in atrophied cases, we need good knowledge of the anatomy and we should be prepared to take advantage of the clinical anatomy as we find it, actually feel it during surgery and implant-bed preparation. We have to be aware that we are working with atrophied maxillae and with rests of basal bone, where clever implant choice and favourable positioning of the implants are fundamental to the success of the treatment. In addition, we must have an excellent anatomical knowledge of the two

jaws and the surrounding hard and soft tissues; To search bone for anchoring in the 2nd or 3rd cortical and to reach these corticals safely, requires experience and sometime patience.

Clinical Case

A 43-year-old female patient (healthy, non-smoker), without systemic diseases asked us for a rehabilitation with implants. During the examination, the patient presents the 1st and 3rd quadrant edentulous, fixed prosthesis from 12 to 28 and another fixed prosthesis bridge from 34 to 45 and finally old 3 biphasic implants with cemented crowns in the lower right mandible (Fig. 1).

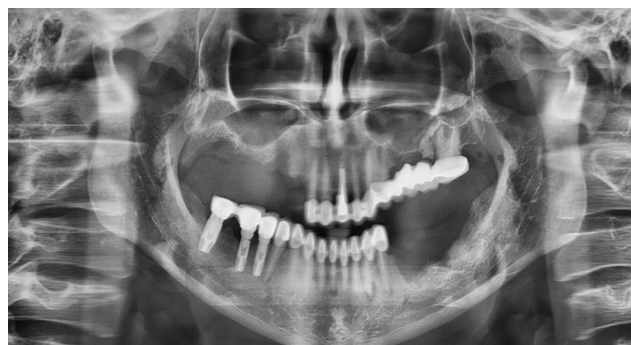


Fig. 1 Preoperative orthopantomography.

On the panoramic overview we find severe atrophy in the edentulous areas, rests of roots, and we assume that there are even residual infections. The patient states that she is very unhappy with the aesthetics of her prosthesis, in addition to the discomfort caused by the leakage of this and the bad odors stemming from it. She also confesses that she is unable to wear the two removable dentures because they cause nausea and they are too unstable in function. All this has led to her request the treatment with implants.

The patient had previously consulted with a number of other treatment providers and he had been told that she was not a candidate for a rehabilitation with implants or that she had to undergo pre-implantological interventions (bilateral sinus lift, bone-block grafts and possible lateralization of the lower alveolar nerve in the 3rd quadrant), Another solution that was given was to place 6 implants in the upper jaw and 4 in the lower jaw, rehabilitating with two hybrid prostheses, which the patient rejected however immediately because of their characteristics.

We offered the following treatments to her: extraction of all teeth and root rests, (since almost all the teeth were very deteriorated by caries, utilization of the already existing three biphasic implants which were well integrated, and to add a number of Strategic Implants as per the rules of Strategic Implantology in the upper jaw (BCS[®] and zygomatic ZSI[®] - Manufacturer: Dr. Ihde Dental AG, 8737 Gommiswald, Switzerland) and in the lower jaw insertion of single-phase implants (KOS[®] and KOS B[®]). An immediate provisional prosthesis of resin and later a definite zirconium prostheses were also part of the treatment plan.

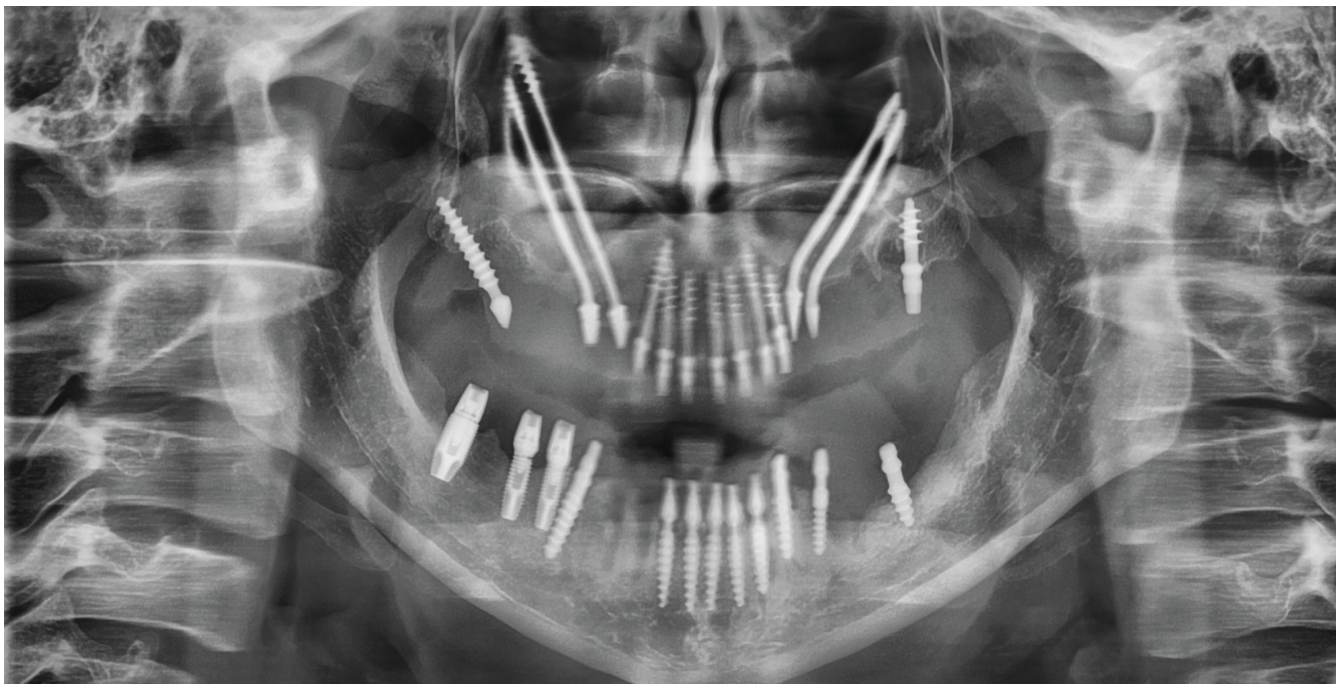


Fig. 2 Postoperative orthopantomography, shows the strategic implants placed; (Basal BCS[®] and zygomatic ZSI[®]) in the upper jaw and KOS[®] single phase implants in the lower jaw as well as the three biphasic implants previously carried by the patient.

Method and Materials

The patient is given an upper and lower TAC scan, and study models and bite registrations were taken for the preparation of the provisional prostheses, so that they would be available on the day of surgery.

On the day of surgery, the bridges were removed and the teeth and roots were extracted and 7 BCS® strategic implants are placed in the anterior zone of the upper jaw, 5 of them looking for anchoring in the floor of the nose and 2 of them in the naso-maxillary buttress.

ZSI® strategic zygomatic implants (2 on the right side and 2 on the left side) are also placed, and in the 2nd quadrant at the level of the tuberosity a strategic BCS® implant with anchorage in the cortical of the sinus floor and the tuberosity, whereas in the first quadrant at the level of the tuberosity a single - phase KOS® implant was placed, looking for the anchorage in the plate of the pterygoid process of the sphenoid bone.

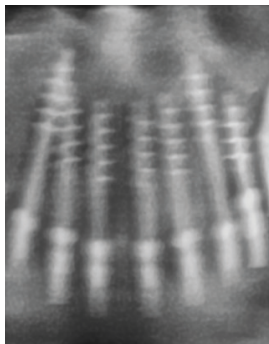


Fig. 3 Radiographic appearance showing the BCS® Strategic Implants in the anterior group and the naso-maxillary buttress.

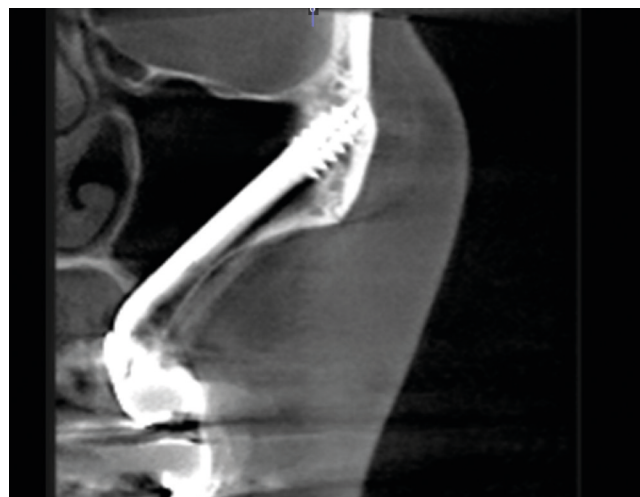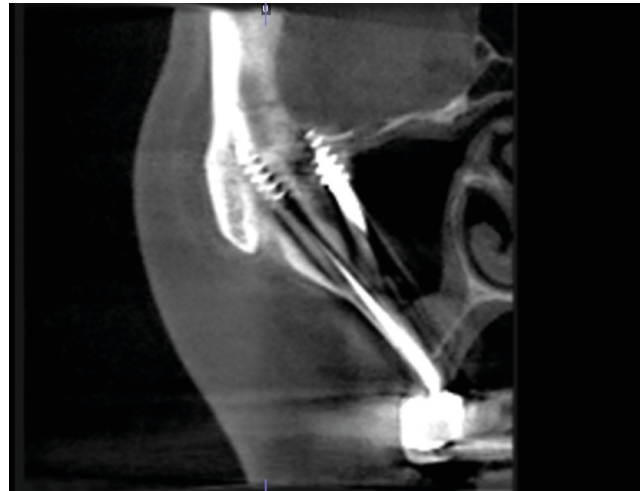


Fig. 4 and 5 Radiographic sections of the scanner where the strategic zygomatic ZSI implants are observed on both sides.

ZSI® strategic zygomatic implants feature a fully polished surface, Ø 4.6 and lengths ranging from 35mm to 55mm. These characteristics allow the placement of implants for anchorage in the body of the zygomatic bone, right through the sinus without causing large destructions or opening of the same, causing maximum a

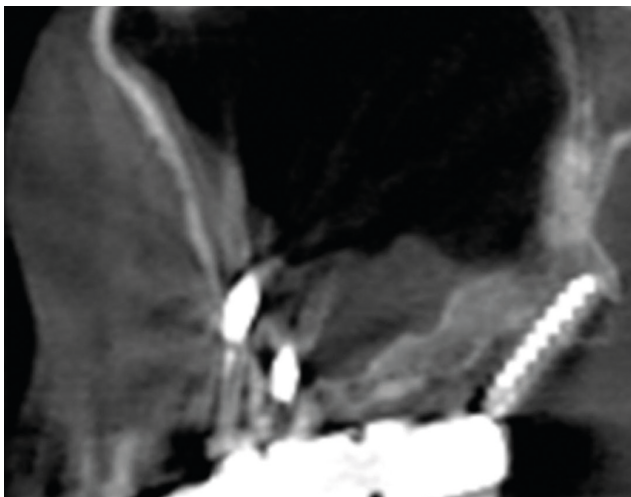
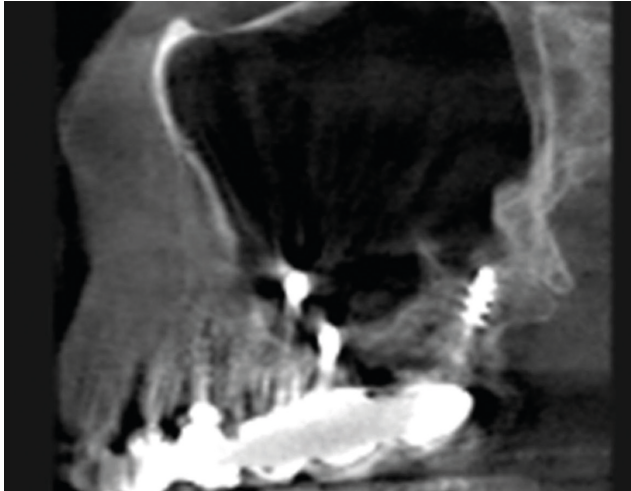


Fig. 6 and 7 Radiographic sections of the scanner showing the most distal implants, one with anchorage in the cortical of the sinus floor and the other in the cortical of the pterygoid.

slight, passager inflammation, facilitating a quick recovery and obtain with these implants a very strong and secure anchorage to fully rehabilitate the patient with his fixed prosthesis.

In the lower jaw, we proceeded to perform the extractions of the teeth and

took advantage of the 3 biphasic implants already carried by the patient. First, 6 KOS® implants were placed in the anterior zone and then 2 more KOS implants in the 3rd quadrant. Another implant was then placed in the 4th quadrant. Once all the implants were placed, the abutments were bent and grinded for better parallelity and hence easier prosthetic handling. We proceeded to take the impressions and bite and vertical registration for the preparation of the fixed prosthesis in the dental laboratory.

Immediately the provisional prostheses were inserted and ground, the occlusion was adjusted. In the rest of the remaining 4 days various try-ins were made, and adjustments of occlusion and masticatory function was done. The finishing and cementing of the definitive zirconium prosthesis was done on day 4. The occlusal and masticatory concept followed the rules given by Ihde & Ihde in the „Cookbook Mastication“. These rules are today the world-wide accepted standard for this technology. Subsequently the appropriate radiographic controls are performed, as well as possible occlusal and masticatory adjustments.

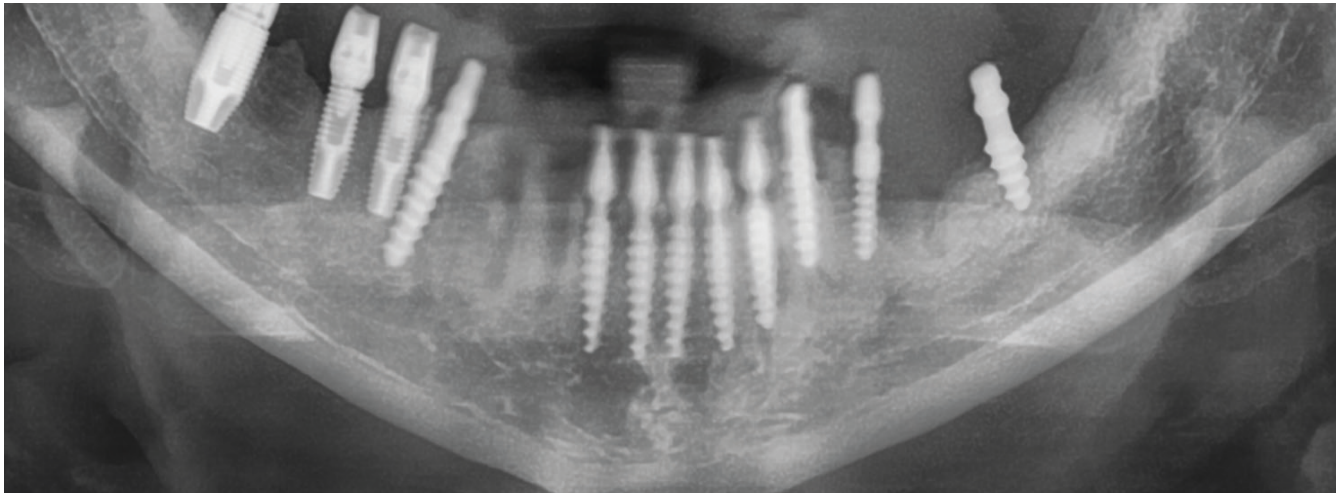


Fig. 8 Radiological image of the lower jaw in which the KOS® implants placed and the 3 biphasic implants carried by the patient can be observed.

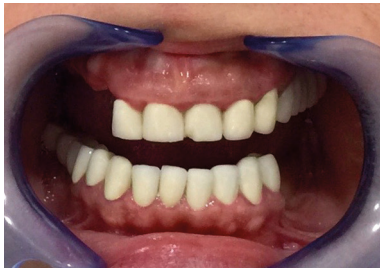

Fig. 9 View of the patient before being operated.

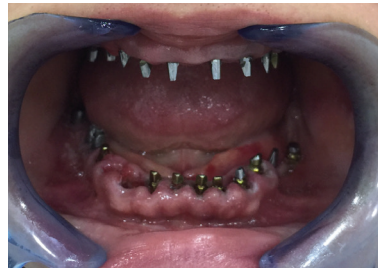

Fig. 10 View of the patient after tooth extractions and implant placement. Grinding of the abutments for better paralellity is already done. There is very little swelling and bleeding. At this stage we proceed to take the impressions and then to restore with the provisional bridges.

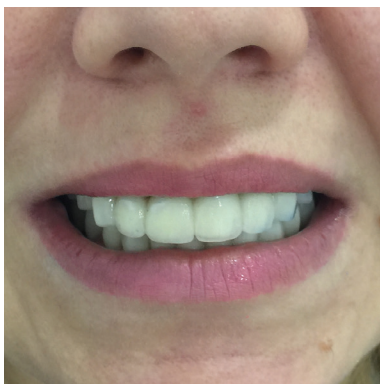

Fig. 11 View of the patient already with the definitive prosthesis in the mouth.

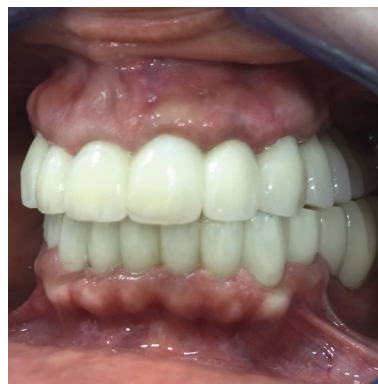

Fig. 12 View of the occlusion adjusted and with the adjustment on the gums.

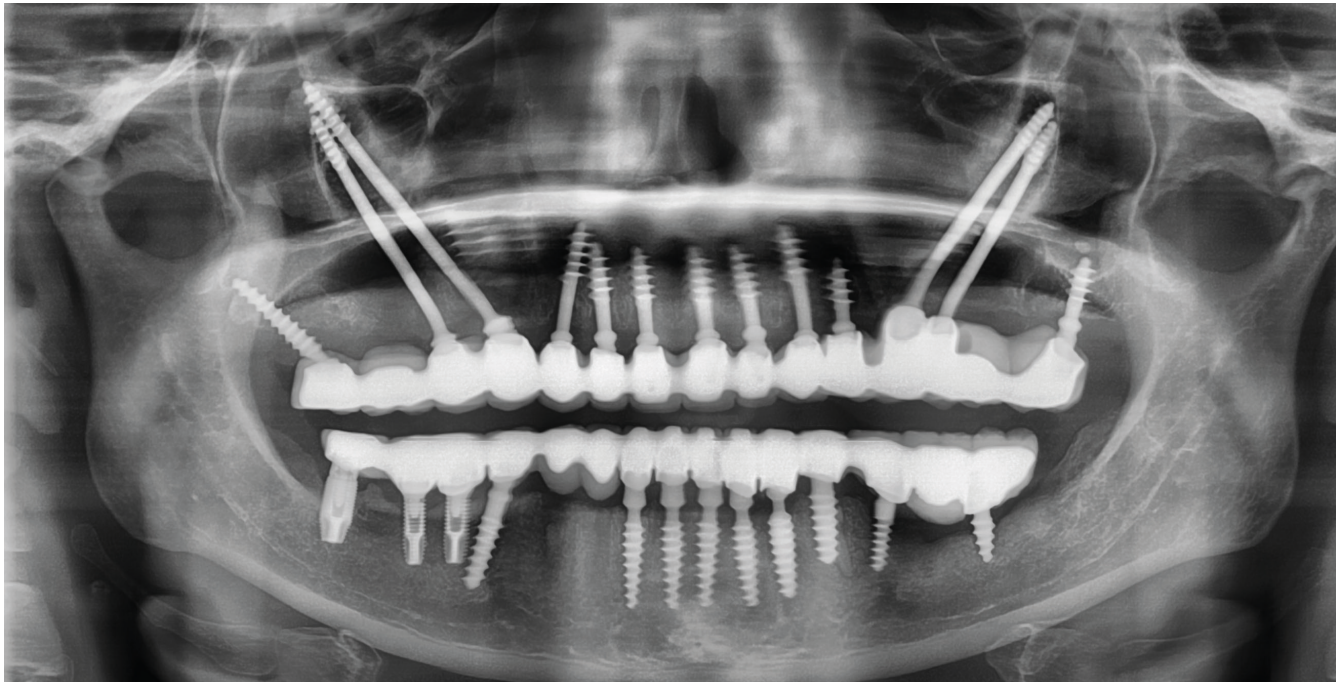


Fig. 13 View of the control orthopantomography with the placed prosthesis. Distal cantilevers must be left without any occlusal and masticatory contact however.

Discussion

It is clear that the beginner in this technology does not get up one morning and begins performing full jaw rehabilitations with strategic implants (basal and zygomatic) in patients with atrophied jaws. This technology requires knowledge and experience, and there is a learning curve which includes also mistakes. But following the steps of Strategic Implant[®] I am totally convinced that through this new didactic and pedagogical approach to rehabilitate with implants, we can realize fixed teeth even in the most difficult situation, where other implantologists have

long given up: it is a big advantage that the neck of the implant can be bent to facilitate the axis of insertion of the prosthesis. In general implants are chosen (according to the clinical situation) long enough to be able to take advantage of the best available bone, the remote cortical areas. And we also can be free from any fear of peri-implantitis. Due to the polished surfaces in thin mucosal penetration diameters we completely exclude the possibility that this disease occurs.

In Strategic Implantology it is necessary to be clear where to place the implants, and to actively looking for the best bone

available, the best and most stable areas of anchorage of the 2nd and/or 3rd cortical. We utilize areas which are not prone to resorption, and allow the transmission of large masticatory loads. We set up a supporting polygon in which the masticatory slopes and occlusal contact-points should be located. The occlusal faces of the prostheses form part of the transmission of the load together with the implants and their position in the bone, all closely together form strategic positions (hence the meaning of the name of the concept „Strategic Implantology“) that makes the success of the treatment.

The combination of all these fragments are thought to conform to a living form which constitutes a whole, as it is; bone, chewing forces and how these are transmitted by the implants and in turn the skeletal architecture of the jaws.

When I sit down with the patient to plan the treatment, knowing well about all the possibilities which the native bone provides, and listening to their wishes and expectations, I can today explain to them that we are going to perform a rehabilitation that meets their demands fully. Also I am satisfied when I can tell them that this result will be reached in a very simple manner and almost right away.

We have been using the technology of the Strategic Implant® (BCS brand: Manufacturer: Dr. Ihde Dental AG/ Switzerland)

for 5 years in our clinic, and we consider this method to be by far superior to the traditional technique which we have used for many years before.

We do not have the intention to return to the previous (historic) technology of 2-stage implantology, nor are we (or the patients) interested to go risky and expensive bone augmentations or even bone transplants.

Some of the big advantages of the new technology are described here. In our view very advantageous is the fact that we have full control over the process of surgical „osseo-fixation“, and we do not depend on „biologic osseo-integration“ for the success of the treatment. When using the old technique we never knew why implants failed. Today, with the new technology we do have a defined treatment protocol and we can know **why** our implants fail if they do. This technology of the Strategic Implant® is a real game changer in dental implantology. It opens a new world of treatment possibilities.

Summary

The evolutionary step to save “Immediate Loading” is to carry out the rehabilitations of our patients with the guidelines of Strategic Implant[®], that guarantee and minimize the risks, increasing the success and satisfaction of our patients in a safe and calm way. It is evident that these rules differ from conventional (historical) concepts in dental implantology and new rules and guidelines must be learned. This is hard but not impossible, and in any case is easier than placing grafts.

The philosophy and methodology for the work with the Strategic Implant[®] is based on the scientific evidence of Immediate Load implants as was laid out in textbooks and articles by Dr. Stefan Ihde and Cols. in the International Implant Foundation (IF, Munich/Germany), with a long biography and large amount of case series. A tremendous amount of research work was carried out all over the world, providing a high level of clinical experience and scientific knowledge, which has greatly simplified the technique and has laid ground for teaching to transmit it to the scientific world of health.

The most important change has to be made in our heads: as treatment providers we have to understand that all our patients can now carry implants and fixed teeth all their life, and that it is not necessary to perform bone grafts or to deli-

ver removable dentures. We only have to follow a new clinical approach and forget what we did in earlier years (although it often worked). The new approach was invented and described by the team around the German dentist Dr. Stefan Ihde (www.ihde.com).

Strategic Implant[®] provides for us the necessary tools to be the number one in our area to be able to provide the best service to our patients and to differentiate us from the rest of the professionals.

The beginner should work under supervision for some time. In any case it is necessary to correct all mistakes immediately. The Strategic Implant[®] revolutionized my way of rehabilitating my patients, they are eternally thankful, just as I am thankful to my teachers. The work with the Strategic Implant has taken my clinic to a new level. Without Strategic Implant[®] guidelines, I would never have rehabilitated my patients in any way so satisfactory for them, realizing for them rehabilitations that allowed immediate and almost care-free life with fixed teeth.

Bibliography

Ihde S., Ihde A.. Introducción al Trabajo con Strategic Implant 1.
International Foundation Publishing.
2015. ISBN 978-3-945889-01-5

Ihde S., Ihde A. Libro de Recetas de la Masticación 4.
International Foundation Publishing.
2015. ISBN 987-3-9851468-8-0

Ihde S., Ihde A. Trabajo de Laboratorio en Implantes Estratégicos 6.
International Foundation Publishing.
2016. ISBN 978-3-945889-13-8

Ihde S., Ihde A., Lysenko V., Konstantinovic V.S.K, Palka L. Nueva Terminología Sistemática de las Áreas de Hueso Cortical para Implantes Oseofijados en Implantología. Jacobs Journal de Anatomía. Jacobs Publishers. 2016.



